



Hereditary diffuse gastric cancer: updated consensus guidelines for clinical management and directions for future research

Rebecca C Fitzgerald, Richard Hardwick, David Huntsman, et al.

J Med Genet 2010 47: 436-444
doi: 10.1136/jmg.2009.074237

Updated information and services can be found at:
<http://jmg.bmj.com/content/47/7/436.full.html>

These include:

References

This article cites 61 articles, 19 of which can be accessed free at:
<http://jmg.bmj.com/content/47/7/436.full.html#ref-list-1>

Article cited in:
<http://jmg.bmj.com/content/47/7/436.full.html#related-urls>

Open Access

This is an open-access article distributed under the terms of the Creative Commons Attribution Non-commercial License, which permits use, distribution, and reproduction in any medium, provided the original work is properly cited, the use is non commercial and is otherwise in compliance with the license. See: <http://creativecommons.org/licenses/by-nc/2.0/> and <http://creativecommons.org/licenses/by-nc/2.0/legalcode>.

Email alerting service

Receive free email alerts when new articles cite this article. Sign up in the box at the top right corner of the online article.

Notes

To order reprints of this article go to:
<http://jmg.bmj.com/cgi/reprintform>

To subscribe to *Journal of Medical Genetics* go to:
<http://jmg.bmj.com/subscriptions>



Hereditary diffuse gastric cancer: updated consensus guidelines for clinical management and directions for future research

Rebecca C Fitzgerald,^{1,2,3} Richard Hardwick,⁴ David Huntsman,⁵ Fatima Carneiro,⁶ Parry Guilford,⁷ Vanessa Blair,⁷ Daniel C Chung,⁸ Jeff Norton,⁹ Krishnadath Ragunath,¹⁰ J Han Van Krieken,¹¹ Sarah Dwerryhouse,¹² Carlos Caldas,^{3,13} on behalf of the International Gastric Cancer Linkage Consortium

► Supplementary figures are published online only. To view these files please visit the journal online (<http://jmg.bmj.com>).

For numbered affiliations see end of article.

Correspondence to

Dr Rebecca Fitzgerald, MRC Cancer Cell Unit, Hutchison/MRC Research Centre, Hills Road, Cambridge CB2 0XZ, UK; rcf@hutchison-mrc.ac.uk

For author footnote see end of the article.

Received 19 October 2009

Accepted 7 December 2009

ABSTRACT

25–30% of families fulfilling the criteria for hereditary diffuse gastric cancer have germline mutations of the *CDH1* (E-cadherin) gene. In light of new data and advancement of technologies, a multidisciplinary workshop was convened to discuss genetic testing, surgery, endoscopy and pathology reporting. The updated recommendations include broadening of *CDH1* testing criteria such that: histological confirmation of diffuse gastric criteria is only required for one family member; inclusion of individuals with diffuse gastric cancer before the age of 40 years without a family history; and inclusion of individuals and families with diagnoses of both diffuse gastric cancer (including one before the age of 50 years) and lobular breast cancer. Testing is considered appropriate from the age of consent following counselling and discussion with a multidisciplinary team. In addition to direct sequencing, large genomic rearrangements should be sought. Annual mammography and breast MRI from the age of 35 years is recommended for women due to the increased risk for lobular breast cancer. In mutation positive individuals prophylactic total gastrectomy at a centre of excellence should be strongly considered. Protocolised endoscopic surveillance in centres with endoscopists and pathologists experienced with these patients is recommended for: those opting not to have gastrectomy, those with mutations of undetermined significance, and in those families for whom no germline mutation is yet identified. The systematic histological study of prophylactic gastrectomies almost universally shows pre-invasive lesions including in situ signet ring carcinoma with pagetoid spread of signet ring cells. Expert histopathological confirmation of these early lesions is recommended.

OVERVIEW

Gastric cancer is the fourth most common cause of cancer worldwide; by 2030 deaths from gastric cancer globally are predicted to have risen from the 15th to the 10th leading cause of mortality from all causes.¹ The vast majority of gastric cancers are sporadic, although it has now been established that 1–3% of gastric cancers arise as a result of inherited gastric cancer predisposition syndromes.^{2–4} Inherited gastric cancers are more commonly of the diffuse type or linitis plastica and are generally referred to as hereditary diffuse gastric cancer

(HDGC). In order for a family to qualify for a diagnosis of HDGC the following criteria have been used^{5,6}:

1. Two or more documented cases of diffuse gastric cancer in first or second degree relatives, with at least one diagnosed before the age of 50, or
2. Three or more cases of documented diffuse gastric cancer in first/second degree relatives, independent of age of onset.

Over 10 years ago linkage analysis implicated germline mutations of the tumour suppressor gene E-cadherin (*CDH1*) as the genetic cause of HDGC.⁷ Shortly afterwards it was estimated that about 25% of families fulfilling the clinical criteria for HDGC would have inactivating *CDH1* germline mutations.⁵ The trigger and molecular mechanism by which the second allele of E-cadherin is subsequently inactivated appears to be diverse and includes methylation, mutation and loss of heterozygosity (LOH)^{8,9} Published data from these families suggest that the penetrance of *CDH1* gene mutations is high,¹⁰ with an estimated risk of >80% (analysis updated in 2008, unpublished data). In other words, carriage of the abnormal E-cadherin gene confers more than an 80% lifetime risk of developing gastric cancer. The causal germline mutations accounting for HDGC cases without an identified defect in *CDH1* are currently unknown.

Increasing awareness of HDGC and the rapid advances in genetic diagnostic tools, endoscopic modalities and the increasing use of laparoscopic surgery led a group of clinical geneticists, gastroenterologists, surgeons, oncologists, pathologists and molecular biologists from nine different countries to convene a workshop in order to update the management guidelines for this condition originally set in 1999 and to propose directions for future research. The workshop discussions were focused on four major topics: (1) genetic counselling and testing; (2) endoscopic surveillance of the stomach and screening for other cancers; (3) prophylactic gastrectomy; and (4) pathological specimen processing and diagnosis.

GENETIC COUNSELLING AND TESTING

Genetic counselling is an essential component of the evaluation and management of HDGC. The genetic evaluation should include a careful three-generation family pedigree, histopathological confirmation of diffuse gastric cancer diagnoses or



This paper is freely available online under the BMJ Journals unlocked scheme, see <http://jmg.bmj.com/site/about/unlocked.xhtml>

precursor lesions, a discussion of lifetime risks of diffuse gastric cancer (updated to >80% in both men and women by age 80) and lobular breast cancer (updated to 60% in women by age 80), and current *CDH1* mutation detection rates (25–50%).^{9–11} Informed consent for genetic testing is required. The counselling process should include not only a formal genetics evaluation but also the input from a multidisciplinary team (MDT) comprising those with relevant expertise in gastric surgery, gastroenterology, pathology, and nutrition. Ideally, the full team should be engaged in both the pre-genetic testing and post-genetic testing phases, but MDT involvement is mandatory in the post-test setting.

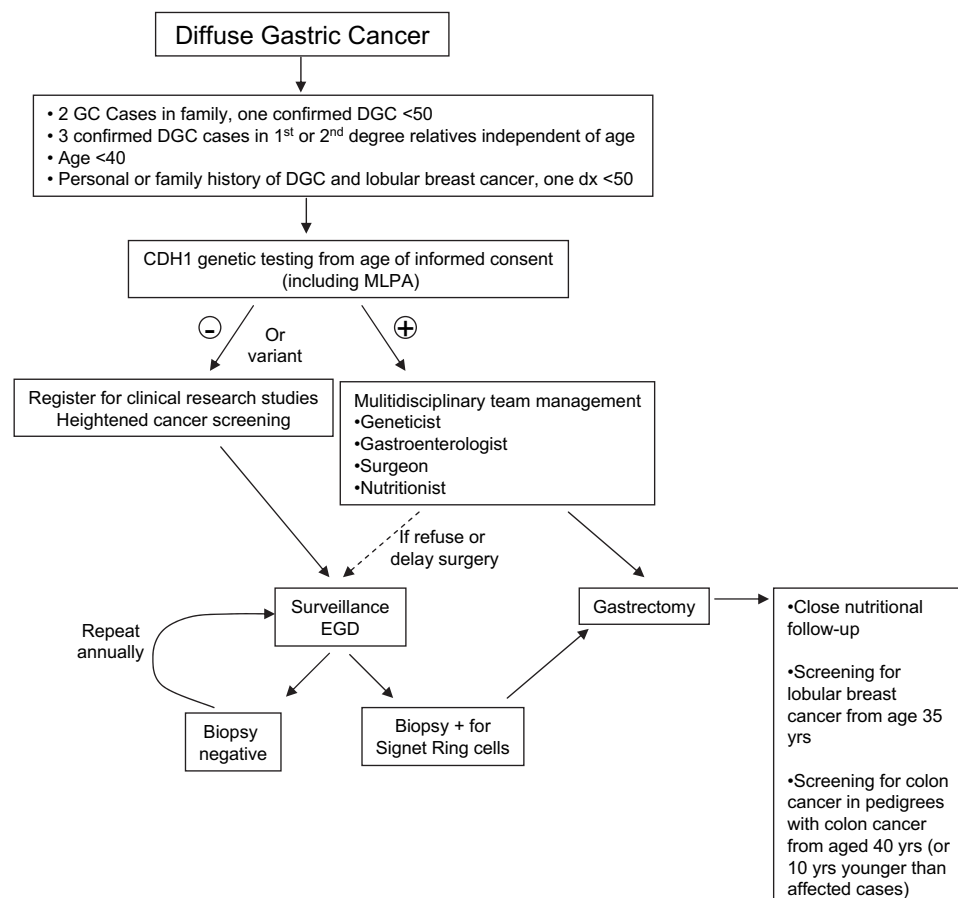
Genetic testing should be initiated in an affected proband. The recommended youngest age at which to offer testing to relatives at risk is not well established. Rare cases of clinically significant diffuse gastric cancer have been reported in affected families before the age of 18, but the overall risk of diffuse gastric cancer before the age of 20 is very low.^{10 12} It was agreed that consideration of genetic testing can begin at the age of consent (16/18 years), but that the testing of family members under 18 years should consider the earliest age of cancer onset in HDGC families from the local population and the psychological, emotional, and physical health of the individual and their family. For example, in New Zealand, *CDH1* mutation carriers have developed gastric cancer in their mid teens; as a consequence, genetic testing begins at 16 years of age, and occasionally 1–2 years before, on a case by case basis.

While the workshop endorsed the clinical definition of hereditary diffuse gastric cancer established in 1999, the criteria for which are stated above,⁵ they also recommended a broader

set of clinical criteria as indications for genetic testing for *CDH1* mutations: namely, relaxation of the restriction for histopathological confirmation of diffuse gastric criteria to one family member, inclusion of individuals with diffuse gastric cancer before the age of 40 years without a family history, and inclusion of individuals and families with diagnoses of both diffuse gastric cancer (including one case below the age of 50 years) and lobular breast cancer (figure 1). In addition, in cases where expert pathologists detect in situ signet ring cells and/or pagetoid spread of signet ring cells adjacent to diffuse type gastric cancer, genetic testing should be considered since this is rarely if ever seen in sporadic cases.¹³

In previous studies the detection rate of *CDH1* mutations was reported to be 25–50%^{11 14 15} when the following criteria were used for inclusion: histologically confirmed diffuse gastric cancer in three first degree family members at any age, or two or more gastric cancers in first degree relatives with at least one confirmed diffuse gastric cancer diagnosed before age 50. Importantly, 4% of these mutation positive families exhibited large germline deletions of *CDH1* that were not detectable by conventional DNA sequencing.¹⁶ Genetic testing on blood for germline mutations should be performed in Clinical Laboratory Improvement Amendments (CLIA) approved molecular diagnostic laboratories or research laboratories with expertise in *CDH1* gene analysis. Analysis of large genomic deletions with multiplex ligation dependent probe amplification (MLPA) or alternative methods (array comparative genomic hybridisation (CGH)) is recommended in cases where DNA sequencing is unrevealing.¹⁶ When blood is not available consideration should be given to testing DNA from paraffin, although any results

Figure 1 Algorithm for management starting from clinical criteria, genetic testing, role of endoscopy and gastrectomy. EGD, oesophagogastroduodenoscopy; MLPA, multiplex ligation dependent probe amplification.



from this material need to be treated cautiously and rigorously confirmed (figure 2).

By genetic criteria, any family with a germline *CDH1* mutation would comprise an HDGC kindred. It is critical that families who meet clinical criteria for HDGC, but do not carry an identifiable *CDH1* mutation or who carry a *CDH1* variant that does not result in a truncated protein, are registered for clinical research studies. Whenever possible, it is important to define the pathogenicity of *CDH1* variants including missense alterations, and the following terminology should be used to classify these variants: silent polymorphism, variant of uncertain significance, likely deleterious variant.¹⁷ Assessment of pathogenicity of such missense mutations relies on *in vitro* assays of E-cadherin dependent cellular aggregation and invasion or *in silico* analyses that predict alterations in E-cadherin protein function based upon conserved evolutionary motifs.^{18–20} Furthermore, it is likely that there are additional genetic loci independent of *CDH1* that confer an increased risk of diffuse gastric cancer, and careful identification and characterisation of such diffuse gastric cancer families without known pathogenic *CDH1* mutations is a prerequisite to defining these loci.

Endoscopic assessment for gastric cancer in individuals with a germline *CDH1* mutation is described in detail under 'Endoscopic surveillance'. The management for those with clinical features suggestive of HDGC but without a germline *CDH1* mutation is not straightforward. We would recommend that intensive endoscopic surveillance should also be offered to families who fulfil the revised criteria as set out in figure 1.

With the increasing evidence for a risk of lobular breast cancer for females who carry pathogenic *CDH1* mutations, it was recommended that enhanced breast cancer screening should be strongly considered. There are currently insufficient data on the role and outcome of breast cancer screening in this population, but the high lifetime risk of breast cancer, particularly the lobular subtype, and the precedents established in other hereditary breast cancer syndromes establish a rationale. Referral to a high risk breast clinic is recommended. For those who choose to undergo screening, we recommend monthly breast self examinations starting at age 35, annual mammogram and breast MRI, and a biannual clinical breast examination. The age of 35 is a pragmatic choice but accurate age related penetrance for breast cancer data is needed in order to confirm the age at which screening should be commenced. In the meantime, in view of the current lack of evidence, breast screening should be carried out in the context of a research protocol as this may permit the formulation of evidence based guidelines in the future. Prophylactic mastectomy cannot be uniformly recommended, but it may be a reasonable option for some women. There are insufficient data to recommend chemoprevention with tamoxifen.

There is also emerging evidence for an increased risk of colon cancer in HDGC families, and these colon cancers can display signet ring cell features (D Huntsman, P Pharoah, personal communications 2009). In *CDH1* families in which colon cancer

is reported, information should be collected concerning the age at diagnosis, whether the affected member(s) are first or second degree relatives, and whether the pathology was mucinous or showed signet ring cells. Depending on these factors, enhanced screening should be considered with colonoscopy beginning at age 40 or 10 years younger than the youngest diagnosis of colon cancer, whichever is younger, and repeated at intervals of 3–5 years. It is imperative that data on colonoscopic screening in these individuals are collated so that these guidelines can be evidenced based in the future.

ENDOSCOPIC SCREENING AND SURVEILLANCE

To clarify the terminology, individuals having endoscopy who do not have a *CDH1* mutation are having screening, whereas mutation positive individuals are undergoing surveillance. The consensus reached at the workshop was that individuals who tested positive for a *CDH1* mutation should be advised to consider prophylactic gastrectomy regardless of any endoscopic findings. However, the timing of this operation may vary according to the preferences and age as well as the physical and psychological fitness of the individual. In patients going forward for gastrectomy a baseline endoscopy should be performed before surgery to look for macroscopic tumour and in order to inform the data on endoscopic detection of microscopic lesions. The information on microscopic disease foci is useful to compare with findings in the surgical resection specimen and hence to inform the data on the likelihood of endoscopic detection of microscopic lesions. For individuals in whom gastrectomy is not currently being pursued (eg, through patient choice), annual endoscopy should be offered in order to ensure that there is no evidence of clinically significant lesions and for research purposes (assuming ethical approval) in order to help understand the natural history of early lesions. Similarly, if the *CDH1* positive individual declines gastrectomy then endoscopic surveillance should be offered under a research protocol. In these individuals surveillance can have the advantage of helping them to come to a decision about the need for gastrectomy, since when microscopic foci of signet ring cells are detected this can help the individual confront their risks from this mutation. For those individuals with mutations of undetermined significance (eg, missense), or in those in whom no mutation can be identified in the index case, then endoscopy has a useful role to play in guiding clinical decision making. Specifically, any malignant lesions detected endoscopically would prompt a referral for gastrectomy. However, all patients should be counselled that in view of the very focal nature of these endoscopically invisible lesions it is quite possible that they will not be detected by random biopsies (figure 1).

ENDOSCOPY PROTOCOL

Individuals should be offered an annual endoscopy that should ideally be performed in a centre with a special interest in, and

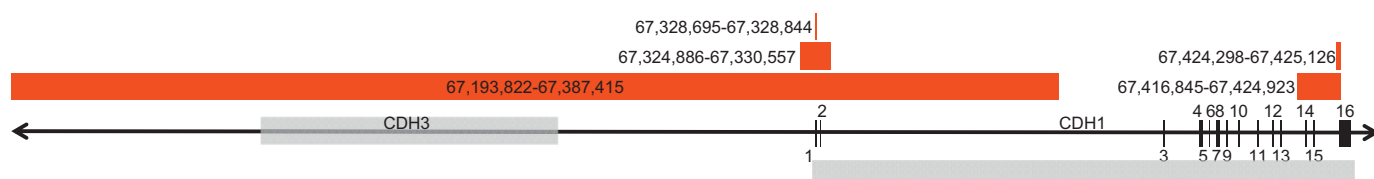


Figure 2 Germline deletions in *CDH1*. The *CDH1* and *CDH3* genes are shown in grey with the exons for *CDH1* indicated. The red areas indicate five deletions detected by multiplex ligation dependent probe amplification.

experience with, this condition. The endoscopy should be performed using a white light high definition endoscope in a dedicated session with at least 30 min allocated to allow for a careful inspection of the mucosa on inflation and deflation, and to allow time for multiple biopsies to be taken. Use of mucolytics such as acetylcysteine may be helpful to obtain good views.

Although there does not appear to be an association between *Helicobacter pylori* infection and HDGC, it is important to test for *H pylori* to document the prevalence of infection in mutation carriers. Furthermore, since *H pylori* is a World Health Organization class 1 carcinogen it is agreed that when individuals are infected it should be eradicated.

Due to the tiny microscopic foci of signet ring cells multiple biopsies are required to maximise the likelihood of diagnosing them.²¹ Targeted biopsying of the body–antral transitional zone of the stomach during endoscopic surveillance has been suggested to increase the diagnostic yield on the basis that in New Zealand Maori families, a predilection was observed for early invasive carcinomas to occur in this area of the stomach.^{12 22} In North American and European families, early invasive carcinoma was identified from the cardia to pre-pyloric region, without evidence of antral clustering.^{21 23–26} In a case series reported by Rogers *et al*,²⁷ 70% of the total foci were localised in the proximal third of the stomach. In a series from the UK²¹ the highest number of foci were again observed in the fundus (44.7%) followed by the body (40.2%). Reasons for the different anatomical localisation of the cancer foci in the aforementioned studies remain to be clarified, but may include environmental factors or differences in the molecular pathogenesis. Therefore it is recommended that any endoscopically visible lesions are targeted and that in addition random sampling of six biopsies is taken for each of the following anatomical zones: antrum, transitional zone, body, fundus, cardia. In all a minimum of 30 biopsies are recommended and a suggested protocol is given in supplementary figure 1.

Chromoendoscopy was initially trialled with Congo red and methylene blue²⁸; however, concerns over the toxicity of Congo red mean that this stain is no longer recommended. Other chromoendoscopic techniques are currently not recommended except in the research setting. Endoscopic technologies are advancing rapidly and the use of trimodal imaging, confocal endomicroscopy and molecular imaging techniques need to be explored (eg, Dunbar and Canto, 2009²⁹).

In order to maximise the yield from endoscopy, specialist histopathology reporting is essential and the guidelines outlined in the pathology section below should be followed.

PROPHYLACTIC GASTRECTOMY

Indications for and timing of surgery

As discussed above, since the penetrance of HDGC is >80%, and since endoscopic surveillance and analysis of gastrectomy specimens suggests that microscopic foci of signet ring cells are almost universally present in mutation carriers (see section entitled Pathology: Classification of microscopic foci and determination of significance), surgery should be strongly considered whenever an at risk family member is found to have a *CDH1* mutation as discussed above. However, the timing of the gastrectomy is debatable. The evidence increasingly suggests that there is likely to be a dormant period in which the signet ring cell adenocarcinoma does not spread or progress since they have a low proliferative index.⁸ This may explain why so many individuals are found to have T-1 N-0 stage tumours after prophylactic gastrectomy.³⁰ However, with our current lack of knowledge of the behaviour of mucosal signet ring cancer cells,

it is recommended that if they are detected on endoscopic biopsies the patient should be advised to undergo a total gastrectomy regardless of age, although it is rare that endoscopy would be recommended before 16 years. *CDH1* mutation positive patients with normal gastric biopsies should be advised to undergo gastrectomy once the genetic testing results are known and once individuals are older than 20 years.¹² Patients under the age of 40 who develop symptomatic invasive diffuse gastric carcinoma have a poor prognosis with as few as 10% having early and curable disease.³¹ As our understanding of the natural history of mucosal signet ring cancer in HDGC improves it may be possible to safely leave some patients until they are older, but until that time it is safer to recommend surgery early in adult life. This has implications for the long term follow-up of prophylactic gastrectomy patients, especially women who are more at risk of iron deficiency anaemia and osteoporosis than men, and re-enforces the need for multidisciplinary teams to care for these patients.

Prophylactic gastrectomy is clearly a significant undertaking. The decision as to if and when to proceed will therefore be influenced by the psychological and physical fitness of the individual and their occupation and other family commitments. Therefore, a multidisciplinary approach to preoperative counselling involving a gastroenterologist, surgeon, dietician, genetic counsellor and specialist nurse is absolutely necessary. This team should work in a high volume cancer centre with low peri-operative mortality rates,³² (<1% for fit patients undergoing total gastrectomy³³). There are now reports to show that pregnancy can be carried to full term following a prophylactic gastrectomy (manuscript submitted) and individuals are able to return to full time work including manual workers. Despite this, the physiological, metabolic and emotional impact of removing a young adults stomach should not be underestimated.

Operation details

The requisite operation is a total gastrectomy with Roux-en-Y reconstruction, ensuring that the jejunio-jejunal anastomosis is at least 50 cm distal to the oesophago-gastric anastomosis to reduce the risk of biliary reflux. The proximal resection line must be across the distal oesophagus to ensure that no gastric cardia mucosa is left behind. There is no need for a radical lymph node dissection in the prophylactic setting since mucosal adenocarcinoma without submucosal invasion has a very low risk indeed of lymph node metastases.³⁴ In view of this, a vagal sparing resection is possible and there are good theoretical reasons why this might give an improved quality of life for patients compared to those undergoing a truncal vagotomy as a byproduct of their gastrectomy.^{35 36} Studies are needed to assess the benefits of this strategy and this group of patients provide a unique population in which to study various aspects of surgical reconstruction such as the provision of a pouch. At the current time, although preliminary studies from Germany and Japan suggest that a pouch may afford an improved quality of life,³⁷ this requires further study and the surgeon should continue to do what he or she is most familiar with. This applies also to whether the preferred surgical approach is open or laparoscopic. Some teams have made good progress at safely introducing a minimally invasive approach to gastric cancer surgery,^{38 39} but any surgeon proposing to do a prophylactic gastrectomy laparoscopically must be able to reassure the patient with audited data that this is without additional risk. These operations are not suitable to be done during a surgeons 'laparoscopic learning curve'. It may also be very helpful for patients to have a chance to talk to other individuals who have been through the same operation to

help them make an informed decision and they know what to expect.

The major issues that worry patients are related to the morbidity and mortality of the gastric cancer compared to that of total gastrectomy. The short term and long term morbidity and mortality of total gastrectomy in these patients does need to be carefully audited. For example, although a prophylactic gastrectomy may improve quality of life as a result of a reduction of the anxiety about stomach cancer, it may worsen because of the side effects associated with the procedure. Following a prophylactic gastrectomy patients have to eat little and often and require support from a dietician. Eating too much too quickly will cause abdominal pain. Dumping syndrome can be troublesome and causes a range of symptoms including pain, nausea, tiredness after eating and diarrhoea. Other problems may include: lactose intolerance, fat malabsorption and steatorrhoea, bacterial overgrowth, and postprandial fullness.^{40 41} Each patient is different after their surgery and it is impossible to predict how affected they will be, but all of them will lose weight and require lifelong vitamin B₁₂ injections and close monitoring for conditions such as anaemia and trace element deficiencies. For most patients, any negative consequences of surgery slowly improve over the first year. Physical function normally returns to normal by 6 months.

The severity and longevity of complications in previously fit young individuals following gastrectomy has not been evaluated and this is an area that requires further research. A central registry of families and patients treated surgically would be very helpful to collect data prospectively on the physical and psychological effects of surgery and improve the care given to patients in the future. One such registry is currently coordinated in Cambridge, UK.

PATHOLOGY: CLASSIFICATION OF MICROSCOPIC FOCI AND DETERMINATION OF SIGNIFICANCE

Currently, there is information available from 96 total gastrectomies in the setting of HDGC, corresponding to published reports.^{12 13 21–28 38 42–47} and unpublished observations. These 96 gastrectomies encompass two groups: (1) 73 correspond to real prophylactic gastrectomies (those performed in *CDH1* mutation carriers who had negative biopsies before surgery); (2) the remaining 23 correspond to total gastrectomies performed in patients in whom early invasive cancer had been identified in preoperative endoscopic biopsies. In the former (real prophylactic gastrectomies), 42 were studied under a research protocol and early invasive signet ring cell carcinoma was identified in 39 cases (93%). In two out of the three cases in which early invasive carcinoma were not identified, tiny foci of in situ signet ring cell carcinoma were observed (unpublished observations). In the 31 prophylactic gastrectomies whose study was not performed under a research protocol, early invasive signet ring cell carcinoma was identified in 25 cases (81%). Concerning the total gastrectomies performed after the preoperative identification of early invasive cancer, all specimens exhibited intramucosal signet ring cell carcinoma (one or more foci).

The need for a systematic study of these prophylactic specimens is highlighted by the case reported by Gaya *et al* in which histopathology was initially reported to be negative,⁴⁸ and which was later submitted to a detailed analysis according to a research protocol. This research analysis led to the identification of four foci positive for early invasive carcinoma.⁴⁹ Similar findings had been previously reported by Lewis *et al*.²⁵

Taken together these systematic studies of prophylactic gastrectomies have led to the proposal of a model for the development of diffuse gastric cancer in germline *CDH1* deleterious mutations carriers which encompasses, as pre-invasive lesions, in situ signet ring carcinoma with pagetoid spread of signet ring cells. The discrepancy between the numerous T1a carcinoma foci and the low number of in situ carcinoma lesions suggests that invasion of the lamina propria by signet ring cells may occur without a morphologically detectable in situ carcinoma.^{23 50}

Special attention should be paid to the two precursor lesions of early invasive signet ring cell carcinoma: (1) in situ signet ring cell carcinoma, corresponding to the presence of signet ring cells within the basal membrane, generally with hyperchromatic and depolarised nuclei; (2) pagetoid spread of signet ring cells below the preserved epithelium of glands and foveolae (figure 3). Criteria for the identification of these lesions should be strictly followed in order to diminish the risk of over diagnosing non-specific changes and distinguishing from lesions that mimic signet ring cells.^{51–53} Therefore, confirmation of these lesions by an independent histopathologist with experience in this area is strongly recommended.

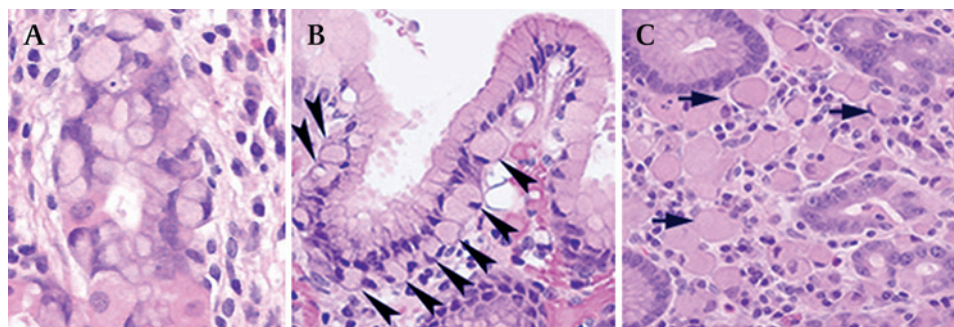
Background changes in the gastric mucosa of prophylactic gastrectomy specimens encompass mild chronic gastritis, sometimes displaying the features of lymphocytic gastritis. Occasionally, an inflammatory granulomatous reaction is observed at the periphery of some collapsing glands. Foveolar hyperplasia and tufting of surface epithelium, focally with globoid change, is also a frequent finding and, in some areas, vacuolisation of surface epithelium is very striking.^{14 23 50} (figure 4).

Additionally, erosions and cysts may be found in non-neoplastic mucosa. In most prophylactic gastrectomies reported so far, intestinal metaplasia and *H pylori* infection are absent (families from North America and Europe). The exceptions are two cases from New Zealand in which *H pylori* infection was identified before surgery (several months or years) and a gastrectomy performed in a Portuguese patient (unpublished). An unsolved issue is the distribution of early lesions of HDGC in the stomach, as discussed above. Therefore it is essential that the location of biopsies and the positive regions within gastrectomy specimens are specifically reported. Additionally, a critical question that remains unanswered is how long early lesions of HDGC can remain indolent until there is emergence of clinical disease that may be rapidly progressive and lethal. Continuing collection of data is essential to help answer these questions—for example, in the rare individuals who opt for endoscopic surveillance until such time as invasive carcinoma is documented, as discussed above.

REPORTING OF GASTRECTOMY SPECIMENS

Macroscopic observation and sampling of prophylactic gastrectomies should follow specific protocols. Fresh gastrectomy specimens should be opened along the greater curve (after painting the margins, dissection of the omentum and retrieval of lymph nodes) and pinned onto a cork board. A life size specimen photo should be used as a template to identify the exact location of the tissue blocks (a schematic map/diagram can be used for that purpose) (figure 5). The possibility of collecting and snap freezing fresh tissue samples from any macroscopic lesion and normal looking mucosa (lesser and greater curvatures, anterior and posterior walls of the stomach) for research purposes should be considered. Overnight fixation in buffered formalin is recommended before sampling for routine histopathology, including

Figure 3 (A) In situ signet ring cell carcinoma: gland with intact basement membrane lined by signet ring cells, with hyperchromatic and depolarised nuclei. (B) Pagetoid spread of signet ring cells below the preserved epithelium of one gland (arrow heads). (C) Focus of invasive intramucosal carcinoma T1a, constituted by signet ring cells (arrows), in the lamina propria.



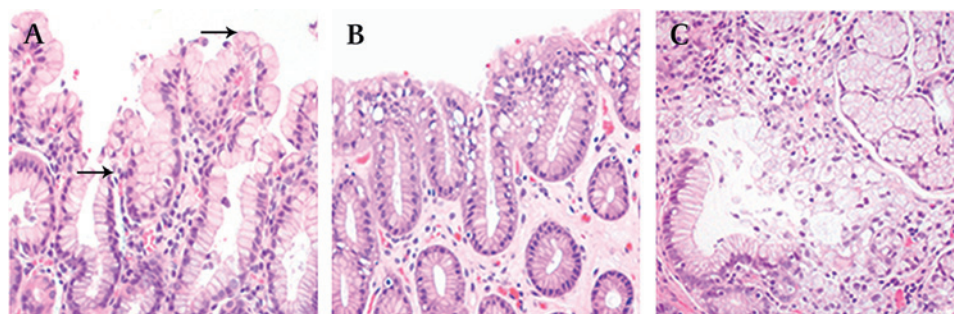
any macroscopically abnormal areas including pale lesions. Sections of the margins should be taken (and labelled) and the remainder of the stomach should be sectioned completely (each section 2 cm×0.3 cm, full thickness) and blocked (paraffin embedded). This usually results in between 100–300 blocks per stomach. The precise location of each section should be marked on the map of the stomach. In case gross lesions are found, these should be precisely localised within the map.

The histological examination should be made using a checklist focusing on the following issues (see supplementary figure 2): (1) features of invasive (intramucosal) carcinoma(s), such as anatomical site (cardia, fundus, body, transitional zone, antrum), location (greater curvature, lesser curvature, anterior wall, posterior wall, circumferential), histological type (WHO, Laurén's⁵⁴ and Carneiro's⁵⁵ classifications), lymphatic, venous and neural invasion (present or absent), precursor lesions such as in situ carcinoma and pagetoid spread (present or absent), status of surgical margins, stromal reaction (lymphocytic infiltrates, eosinophilia, desmoplasia and granulomatous reaction); (2) general features of non-neoplastic mucosa (chronic inflammation, activity, *H pylori* microorganisms, intraepithelial lymphocytes, intestinal metaplasia, dysplasia); (3) specific features of non-neoplastic mucosa (hyperplastic changes, tufting of surface epithelium, vacuolisation of surface/foveolar epithelium, ulcers, erosions, granulomas, cysts). In case the final report is presented in the format of a checklist, a summary should be presented at the end.

In case of restricted time available due to the pathologist's workload and lab resourcing, and sometimes requests from the patients for return of gross specimens, it is not possible to perform a full embedding of the stomach on a routine basis. In such cases the minimum examination of a macroscopically normal gastrectomy should include:

1. Proximal and distal margins to confirm all of the gastric mucosa has been resected.
2. All lymph nodes should be sampled as per a usual gastrectomy.

Figure 4 (A) Foveolar hyperplasia (between arrows); in comparison to normal epithelium (below) cells are globoid (rounded with abundant cytoplasm). (B) Vacuolisation of the cytoplasm of superficial and foveolar cells. (C) Granulomatous reaction at the periphery of a disrupted gland.



3. Photograph.

4. Mapped sampling from all zones; antrum, transitional zone (angularis incisura), body and fundus.

5. If no foci of carcinoma are found, then to go back to the specimen and take more blocks. Step4 repeated as time, workload and resourcing allow.

The report should follow the checklist in supplementary figure 2. In the event of not finding foci of signet ring cell carcinoma, the gastrectomy should not be reported as negative for carcinoma, but as 'no carcinoma found in xx% of mucosa examined'.

USE OF IMMUNOSTAINING AND HISTOCHEMICAL STAINS

Diffuse or signet ring cell carcinomas are easily detected on Haematoxylin and eosin (H&E) sections. The use of histochemical stains for neutral mucins, such as periodic acid-Schiff (PAS) and diastase digestion, may be useful for the detection or confirmation of tiny intramucosal carcinomas in which the neoplastic cells are dispersed among preserved foveolae and glands. E-cadherin immunoexpression has been shown to be reduced or absent in early invasive gastric carcinomas, contrasting with the normal membranous E-cadherin expression in adjacent non-neoplastic mucosa, in keeping with a clonal origin of the cancer foci. In pagetoid spread lesions and in situ carcinomas E-cadherin immunoexpression was also shown to be reduced or absent.²³ However, one should be aware that E-cadherin expression is not always reduced or absent, depending on the mutation localisation and specific mechanisms of inactivation of the wild type allele.

CENTRES OF EXCELLENCE FOR PATHOLOGICAL DIAGNOSIS

Experience in the observation of prophylactic gastrectomies for HDGC is quite limited in most pathology departments due to the rarity of these surgical specimens. Additionally, the routine workload of most centres is incompatible with the detailed observation of hundreds of sections as those obtained after total

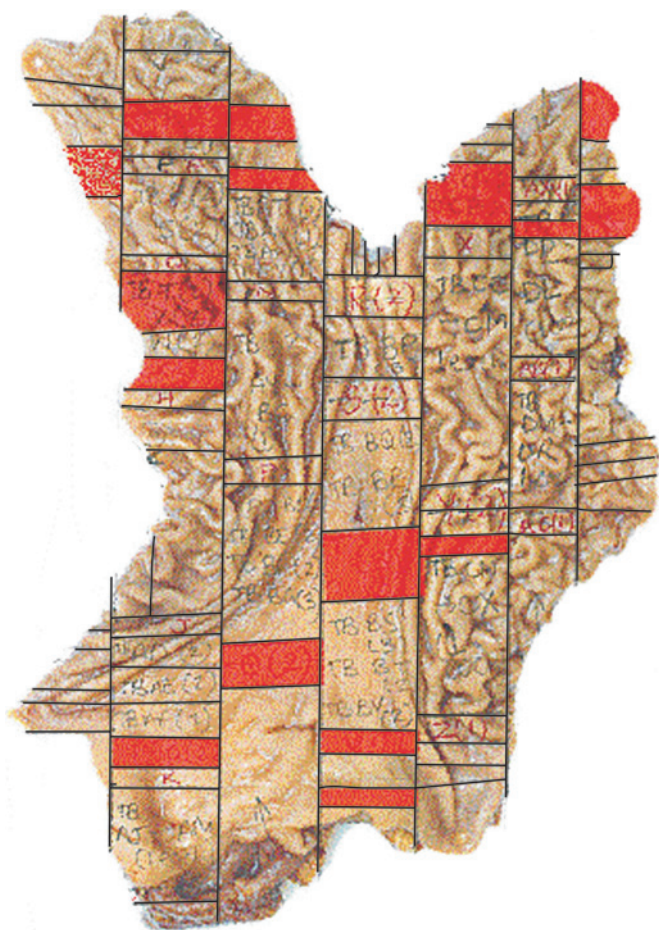


Figure 5 An example of a gastrectomy specimen processed for pathology.

blocking of those stomachs according to the recommendations as described above.

In order to increase the experience of pathologists and the accuracy of the diagnosis, namely of precursor lesions of HDGC, it would be useful to build a virtual bank of the different types of lesions observed in the setting of HDGC. Furthermore, the workshop agreed that the use of scanned slides to be submitted for evaluation by experienced pathologists in the field should be seriously considered.

To account for the thorough observation of all prophylactic gastrectomies performed worldwide, a few centres should be identified in different geographic regions (Australia/New Zealand, Canada/USA/Europe) to which material from prophylactic gastrectomies (whole stomach, paraffin blocks, glass slides and/or virtual slides) should be sent whenever necessary. These centres could also hold a collection of gastrectomy specimens obtained from individuals with HDGC, since these are a valuable learning resource.

QUESTIONS ARISING ON MOLECULAR PATHOGENESIS AND NEED OF RESEARCH

The diminished or absent E-cadherin immunoreactivity observed in HDGC and its precursor lesions is consistent with bi-allelic dysfunction of the *CDH1* gene. Both alterations (first hit, corresponding to germline mutation in this model, and second hit by a somatic mechanism for gene inactivation) are expected to lead to inactivation of *CDH1* below a critical threshold which determines initiation of the neoplastic process.^{56 57}

In the setting of HDGC, a few tumours have been analysed for second hit inactivation mechanisms. Although somatic mutations of *CDH1* do occur,^{8 58} promoter hypermethylation appears to be the most frequent second hit mechanism.^{8 59 60} Recently, it was shown that the second hit in *CDH1* may be different in primary tumours and metastases, epigenetic changes (promoter hypermethylation) being more frequent in HDGC primary tumours and LOH in metastases.⁹ A thorough analysis of the mechanisms responsible for the second hit inactivation of *CDH1* in the very early lesions of HDGC is necessary to define strategies for chemoprevention.

Alterations in other tumour suppressor genes and oncogenes are expected to play a role in the pathophysiology of HDGC, although this issue has rarely been explored in the literature. Humar *et al*⁶¹ have described that diffuse gastric cancer initiation seems to occur at the proliferative zone of the gastric epithelium and correlates with absent or reduced expression of junctional proteins. Moreover, these authors suggest that progression is associated with poor differentiation, increased proliferation, activation of the c-Src system, and epithelial–mesenchymal transition. It remains to be seen if c-Src kinase activation marks the development of early diffuse gastric cancer. Identification of the molecular mechanisms underlying disease progression is mandatory to explain why some early intramucosal carcinomas remain indolent for undefined periods of time, while others progress to higher stage, clinically significant gastric cancer.

In summary, everyone at the workshop was in agreement that there should be a group of centres caring for these patients throughout the world and we should have a system to collate data centrally using website resources, for example. For a rare condition with such profound implications for the families affected, it is essential that clinical experiences and research progress are combined in order to benefit patient management.

Author affiliations

¹MRC Cancer Cell Unit, Hutchison/MRC Research Centre, Cambridge, UK

²Department Gastroenterology, Addenbrooke's Hospital, Cambridge, UK

³Cambridge NIHR Biomedical Research Centre, University of Cambridge NHS Foundation Trust

⁴Department Oesophago-Gastric Surgery, Addenbrooke's Hospital, Cambridge, UK

⁵British Columbia Cancer Agency, Vancouver, Canada

⁶Institute of Molecular Pathology and Immunology of the University of Porto (IPATIMUP) and Medical Faculty of Porto/Hospital S. João, Porto, Portugal

⁷Biochemistry Department, University of Otago, New Zealand

⁸GI Cancer Genetics Clinic, Gastrointestinal Unit, Massachusetts General Hospital, Boston

⁹Division of General Surgery, Stanford University, USA

¹⁰Wolfson Digestive Diseases Centre, Queens Medical Centre, Nottingham University Hospitals NHS Trust

¹¹Department of Pathology, Radboud University Nijmegen Medical Centre, Nijmegen, The Netherlands

¹²Cancer Research UK Familial Gastric Cancer Study, University Department of Oncology, Addenbrooke's Hospital, Cambridge, UK

¹³Cancer Research UK Cambridge Research Institute and Department of Oncology, University of Cambridge, Li Ka Shing Centre

Author footnote

These guidelines are the result of consensus statements agreed during the seventh workshop of the International Gastric Cancer Linkage Consortium (IGCLC) held on 20–21 November 2008 at the Cambridge Research Institute, Cambridge UK 2008

Workshop participants: Mr William Allum, Consultant Upper GI Surgeon, Royal Marsden Hospital, London, UK; Mr Stephen Attwood, Consultant Upper GI and Laparoscopic Surgeon, Northumbria Healthcare Trust, UK; Dr Vanessa Blair, Surgical Research Fellow, University of Otago, New Zealand; Nicola Bradshaw, MacMillan Cancer Genetic Counsellor, Glasgow, UK; Dr Carole Brewer, Consultant in Clinical Genetics, Royal Devon & Exeter Hospital, UK; Prof. Carlos Caldas, Professor of Cancer Medicine, CR UK Cambridge Research Institute, UK; Prof. Fatima Carneiro, Professor of Pathology, Institute of Molecular Pathology and Immunology of the University of Porto (IPATIMUP) and Medical Faculty of Porto/Hospital S. João, Porto, Portugal; Dr Annetiekie Cats, Head of Department of Gastroenterology and Hepatology,

Netherlands Cancer Institute/Antoni van Leeuwenhoek Hospital, Plesmanlaan, Amsterdam, The Netherlands; Dr Amanda Charlton, Hon. Senior Clinical Lecturer, Faculty Medical and Health Sciences, Imoversity of Auckland, New Zealand; Daniel C. Chung MD, Director, GI Cancer Genetics Clinic, Gastrointestinal Unit, Massachusetts General Hospital, Boston; Associate Professor in Medicine, Harvard Medical School, USA; Dr Trevor Cole, Geneticist, Birmingham Women's Hospital, Edgbaston, Birmingham, UK; Dr Gianni Corso, Department of General Surgery and Surgical Oncology, University of Siena, Italy; Prof. Jean Crabtree, Professor of Experimental Pathology, Leeds Institute Molecular Medicine, University of Leeds, UK; Dr Huw Dorkins, Consultant Clinical Geneticist, The Kennedy-Galton Centre, Harrow, UK; Sarah Downing, Genetic Counsellor, Addenbrooke's Hospital, Cambridge, UK; Dr Jason Dunn, Research Fellow, UCLH, London, UK; Sarah Dwerryhouse, Co-ordinator, Cancer Research UK Familial Gastric Cancer Study, UK; Dr Peter Fairclough, Consultant Gastroenterologist, Barts and The London NHS Trust, UK; Dr Rebecca Fitzgerald, Programme Leader & Hon. Consultant Gastroenterologist, Cambridge, UK; Dr James Going, Senior Lecturer, Pathology, Glasgow Royal Infirmary, UK; Samantha Grimes, Dietician, Addenbrooke's Hospital, Cambridge, UK; Prof. Parry Guilford, Associate Professor, Cancer Genetics Laboratory, University of Otago, New Zealand; Mr Mike Hallissey, Consultant in General Surgery, Queen Elizabeth Hospital, Birmingham, UK; Nina Hollowell PhD, Public Health Sciences, Pathology, University of Edinburgh, UK; Mr Richard Hardwick, Consultant Upper GI Surgeon, Cambridge, UK; Prof. Nicoline Hoogerbrugge, PI molecular basis of hereditary cancer, Associate Professor and Head of Hereditary Cancer Clinic, Radboud University Nijmegen Medical Centre, The Netherlands; Dr Laetitia Huiart, Department of Oncogenetics, Institut Paoli-Calmettes, Marseille, France; Prof. David Huntsman, British Columbia Cancer Agency, Vancouver, Canada; Dr Gisela Keller, Institute of Pathology, Munich, Germany; Dr Ann Kershaw, Consultant Genetic Counsellor, Addenbrooke's Hospital, Cambridge, UK; Dr Ajith Kumar, Consultant in Clinical Genetics, Great Ormond Street Hospital, London, UK; Dr Laurence Lovat, Consultant Gastroenterologist & Senior Lecturer in Laser Medicine, UCLH, London, UK; Professor Ken McColl, Head of Division of Gastroenterology, Gardiner Institute, Glasgow, UK; Dr Shane McKee, Consultant Clinical Geneticist, Belfast City Hospital, UK; Dr Jeffrey Norton, Professor of Surgery, Stanford University, USA; Dr Maria O'Donovan, Pathologist, Addenbrooke's Hospital, Cambridge, UK; Dr Carla Oliveira, Research Scientist, IPATIMUP, Portugal; Dr Sylvianne Olschwang, Geneticist, Department of Molecular Oncology, Institut Paoli-Calmettes, Marseille, France and INSERM U891; Centre de Recherche en Cancérologie de Marseille, France; Mr Bijendra P Patel, Clinical Senior Lecturer and Consultant Upper GI Surgeon, Director of Surgical Skills Unit, Barts and The Royal London Hospital NHS Trust, UK; Dr Joan Paterson, Consultant, Clinical Genetics, Cambridge, UK; Dr Corrado Pedrazzani, Clinical-Research Senior Fellow in Surgical Oncology, Department of Human Pathology and Oncology, Unit of Surgical Oncology, University of Siena, Italy; Dr Paul Pharoah, Genetic Epidemiologist, Cambridge, UK; Dr Krish Ragunath, Associate Professor in Endoscopy, Wolfson Digestive Diseases Centre, Queens Medical Centre, Nottingham University Hospitals NHS Trust, UK; Dr Franco Roviello, Associate Professor of Surgery, Department of General Surgery and Surgical Oncology, University of Siena, Italy; Dr Vicki Save, Consultant Histopathologist, Royal Infirmary of Edinburgh, UK; Dr Siobhan Sengupta, Lecturer in Human Genetics, UCL Centre for Preimplantation Genetic Diagnosis, London, UK; Dr Raquel Seruca, Research Scientist, IPATIMUP, Portugal; Manish A. Shah MD, Medical Oncologist, Memorial Sloan Kettering Cancer Centre, New York, USA; Dr Hubert Stein, Professor of Surgery, Paracelsus Private Medical University, Salzburg, Austria; Dr Nicola Van Krieken, Pathologist, Amsterdam, The Netherlands; Prof. dr. J Han van Krieken, PI in Pathology, Radboud University Nijmegen Medical Centre, The Netherlands; Dr Matthew Wallis, Consultant Radiologist, Addenbrooke's Hospital, Cambridge, UK; Dr Debrah Wirtzfeld, Head, Surgical Oncology, CancerCare Manitoba, Associate Professor of Surgery, Oncology and Community Health Sciences, University of Manitoba, Canada. The workshop participants wish to thank Christine Fox for secretarial support and for all travel and accommodation arrangements.

Acknowledgements The 7th (Cambridge, Vancouver, Porto, Munich, Siena, Seoul, and Cambridge) workshop of the International Gastric Cancer Linkage Consortium was made possible by generous sponsorship from the British Society of Gastroenterology.

Funding Other Funders: British Society of Gastroenterology; Cancer Research UK.

Competing interests None.

Provenance and peer review Not commissioned; externally peer reviewed.

REFERENCES

1. **Mathers CD**, Loncar D. Projections of global mortality and burden of disease from 2002 to 2030. *PLoS Med* 2006;**3**:e442.
2. **Vasen HF**, Wijnen JT, Menko FH, Kleibeuker JH, Taal BG, Griffioen G, Nagengast FM, Meijers-Heijboer EH, Bertario L, Varesco L, Bisgaard ML, Mohr J, Fodde R, Khan PM. Cancer risk in families with hereditary nonpolyposis colorectal cancer diagnosed by mutation analysis. *Gastroenterology* 1996;**110**:1020–7.
3. **Varley JM**, McGown G, Thorncroft M, Tricker KJ, Teare MD, Santibanez-Koref MF, Martin J, Birch JM, Evans DG. An extended Li-Fraumeni kindred with gastric carcinoma and a codon 175 mutation in TP53. *J Med Genet* 1995;**32**:942–5.
4. **La Vecchia C**, Negri E, Franceschi S, Gentile A. Family history and the risk of stomach and colorectal cancer. *Cancer* 1992;**70**:50–5.
5. **Caldas C**, Carneiro F, Lynch HT, Yokota J, Wiesner GL, Powell SM, Lewis FR, Huntsman DG, Pharoah PD, Jankowski JA, MacLeod P, Vogelsang H, Keller G, Park KG, Richards FM, Maher ER, Gayther SA, Oliveira C, Grehan N, Wight D, Seruca R, Roviello F, Ponder BA, Jackson CE. Familial gastric cancer: overview and guidelines for management. *J Med Genet* 1999;**36**:873–80.
6. **Oliveira C**, Bordin MC, Grehan N, Huntsman D, Suriano G, Machado JC, Kiviluoto T, Aaltonen L, Jackson CE, Seruca R, Caldas C. Screening E-cadherin in gastric cancer families reveals germ-line mutations only in hereditary diffuse gastric cancer kindred. *Hum Mutat* 2002;**19**:510–17.
7. **Guilford P**, Hopkins J, Harraway J, McLeod M, McLeod N, Harawira P, Taite H, Scouler R, Miller A, Reeve AE. E-cadherin germline mutations in familial gastric cancer. *Nature* 1998;**392**:402–5.
8. **Barber M**, Murrell A, Ito Y, Maia AT, Hyland S, Oliveira C, Save V, Carneiro F, Paterson AL, Grehan N, Dwerryhouse S, Lao-Sirieix P, Caldas C, Fitzgerald RC. Mechanisms and sequelae of E-cadherin silencing in hereditary diffuse gastric cancer. *J Pathol* 2008;**216**:295–306.
9. **Oliveira C**, Sousa S, Pinheiro H, Karam R, Bordeira-Carriço R, Senz J, Kaurah P, Carvalho J, Pereira R, Gusmão L, Wen X, Cipriano MA, Yokota J, Carneiro F, Huntsman D, Seruca R. Quantification of epigenetic and genetic 2nd hits in CDH1 during hereditary diffuse gastric cancer syndrome progression. *Gastroenterology* 2009;**136**:2137–48.
10. **Pharoah PD**, Guilford P, Caldas C. Incidence of gastric cancer and breast cancer in CDH1 (E-cadherin) mutation carriers from hereditary diffuse gastric cancer families. *Gastroenterology* 2001;**121**:1348–53.
11. **Kaurah P**, MacMillan A, Boyd N, Senz J, De Luca A, Chun N, Suriano G, Zoor S, Van Manen L, Gilpin C, Nikkel S, Connolly-Wilson M, Weissman S, Rubinstein WS, Sebald C, Greenstein R, Stroop J, Yim D, Panzini B, McKinnon W, Greenblatt M, Wirtzfeld D, Fontaine D, Coit D, Yoon S, Chung D, Lauwers G, Pizzuti A, Vaccaro C, Redal MA, Oliveira C, Tischkowitz M, Olschwang S, Gallinger S, Lynch H, Green J, Ford J, Pharoah P, Fernandez B, Huntsman D. Founder and recurrent CDH1 mutations in families with hereditary diffuse gastric cancer. *JAMA* 2007;**297**:2360–72.
12. **Blair V**, Martin I, Shaw D, Winslip I, Kerr D, Arnold J, Harawira P, McLeod M, Parry S, Charlton A, Findlay M, Cox B, Humar B, More H, Guilford P. Hereditary diffuse gastric cancer: diagnosis and management. *Clin Gastroenterol Hepatol* 2006;**4**:262–75.
13. **Oliveira C**, Moreira H, Seruca R, de Oliveira MC, Carneiro F. Role of pathology in the identification of hereditary diffuse gastric cancer: report of a Portuguese family. *Virchows Arch* 2005;**446**:181–4.
14. **Oliveira C**, Seruca R, Carneiro F. Genetics, pathology, and clinics of familial gastric cancer. *Int J Surg Pathol* 2006;**14**:21–33.
15. **Suriano GYS**, Ferreira P, Senz J, Kaurah P, Ford JM, Longacre TA, Norton JA, Chun N, Young S, Oliveira MJ, Macgillivray B, Rao A, Sears D, Jackson CE, Boyd J, Yee C, Deters C, Pai GS, Hammond LS, McGivern BJ, McDughey D, Sartz D, Arun B, Delschlagger BK, Upton MP, Neufeld-Kaiser W, Silva OE, Donenberg TR, Kooby DA, Sharma S, Jonsson BA, Gronberg H, Gallinger S, Seruca R, Lynch H, Huntsman DG. Characterization of a recurrent germ line mutation of the e-cadherin gene: implications for genetic testing and clinical management. *Clin Cancer Res* 2005;**11**:5401–9.
16. **Oliveira C**, Senz J, Kaurah P, Pinheiro H, Sanges R, Haegert A, Corso G, Schouten J, Fitzgerald R, Vogelsang H, Keller G, Dwerryhouse S, Grimmer D, Chin SF, Yang HK, Jackson CE, Seruca R, Roviello F, Stupka E, Caldas C, Huntsman D. Germline CDH1 deletions in hereditary diffuse gastric cancer families. *Hum Mol Genet* 2009;**18**:1545–55.
17. **Plon SE**, Eccles DM, Easton D, Foulkes WVD, Genuardi M, Greenblatt MS, Hogervorst FB, Hoogerbrugge N, Spurdle AB, Tavtigian SV; IARC Unclassified Genetic Variants Working Group. Sequence variant classification and reporting: recommendations for improving the interpretation of cancer susceptibility genetic test results. *Hum Mutat* 2008;**29**:1282–91.
18. **Ng PC**, Henikoff S. Accounting for human polymorphisms predicted to affect protein function. *Genome Res* 2002;**12**:436–46.
19. **Suriano G**, Oliveira C, Ferreira P, Machado JC, Bordin MC, De Wever O, Bruyneel EA, Moguilevsky N, Grehan N, Porter TR, Richards FM, Hruban RH, Roviello F, Huntsman D, Mareel M, Carneiro F, Caldas C, Seruca R. Identification of CDH1 germline missense mutations associated with functional inactivation of the E-cadherin protein in young gastric cancer probands. *Hum Mol Genet* 2003;**12**:575–82.
20. **Suriano G**, Seixas S, Rocha J, Seruca R. A model to infer the pathogenic significance of CDH1 germline missense variants. *J Mol Med* 2006;**84**:1023–31.
21. **Barber ME**, Save V, Carneiro F, Dwerryhouse S, Lao-Sirieix P, Hardwick RH, Caldas C, Fitzgerald RC. Histopathological and molecular analysis of gastrectomy specimens from hereditary diffuse gastric cancer patients has implications for endoscopic surveillance of individuals at risk. *J Pathol* 2008;**216**:286–94.
22. **Charlton A**, Blair V, Shaw D, Parry S, Guilford P, Martin IG. Hereditary diffuse gastric cancer: predominance of multiple foci of signet ring cell carcinoma in distal stomach and transitional zone. *Gut* 2004;**53**:814–20.
23. **Carneiro F**, Huntsman DG, Smyrk TC, Owen DA, Seruca R, Pharoah P, Caldas C, Sobrinho-Simões M. Model of the early development of diffuse gastric cancer in E-cadherin mutation carriers and its implications for patient screening. *J Pathol* 2004;**203**:681–7.
24. **Huntsman DG**, Carneiro F, Lewis FR, MacLeod PM, Hayashi A, Monaghan KG, Maung R, Seruca R, Jackson CE, Caldas C. Early gastric cancer in young, asymptomatic carriers of germ-line E-cadherin mutations. *N Engl J Med* 2001;**344**:1904–9.

25. **Lewis FR**, Mellinger JD, Hayashi A, Lorelli D, Monaghan KG, Carneiro F, Huntsman DG, Jackson CE, Caldas C. Prophylactic total gastrectomy for familial gastric cancer. *Surgery* 2001;**130**:612–17; discussion 617–19.
26. **Chun YS**, Lindor NM, Smyrk TC, Petersen BT, Burgart LJ, Guilford PJ, Donohue JH. Germline E-cadherin gene mutations: is prophylactic total gastrectomy indicated? *Cancer* 2001;**92**:181–7.
27. **Rogers WM**, Dobo E, Norton JA, Van Dam J, Jeffrey RB, Huntsman DG, Kingham K, Chun N, Ford JM, Longacre TA. Risk-reducing total gastrectomy for germline mutations in E-cadherin (CDH1): pathologic findings with clinical implications. *Am J Surg Pathol* 2008;**32**:799–809.
28. **Shaw DBV**, Framp A, Harawira P, McLeod M, Guilford P, Parry S, Charlton A, Martin I. Chromoendoscopic surveillance in hereditary diffuse gastric cancer: an alternative to prophylactic gastrectomy? *Gut* 2005;**54**:461–8.
29. **Dunbar K**, Canto M. Confocal endomicroscopy. *Curr Opin Gastroenterol* 2008;**24**:631–7.
30. **Norton JA**, Ham CM, Van Dam J, Jeffrey RB, Longacre TA, Huntsman DG, Chun N, Kurian AW, Ford JM. CDH1 truncating mutations in the E-cadherin gene: an indication for total gastrectomy to treat hereditary diffuse gastric cancer. *Ann Surg* 2007;**245**:873–9.
31. **Koea JB**, Karpeh MS, Brennan MF. Gastric cancer in young patients: demographic, clinicopathological, and prognostic factors in 92 patients. *Ann Surg Oncol* 2000;**7**:346–51.
32. **Brennan MF**. Safety in numbers. *Br J Surg* 2004;**91**:653–4.
33. **Brennan MF**. Pre-emptive surgery and increasing demands for technical perfection. *Br J Surg* 2003;**90**:3–4.
34. **Sano T**, Kobori O, Muto T. Lymph node metastasis from early gastric cancer: endoscopic resection of tumour. *Br J Surg* 1992;**79**:241–4.
35. **Peyre CG**, DeMeester SR, Rizzetto C, Bansal N, Tang AL, Ayazi S, Leers JM, Lipham JC, Hagen JA, DeMeester TR. Vagal-sparing esophagectomy: the ideal operation for intramucosal adenocarcinoma and Barrett with high-grade dysplasia. *Ann Surg* 2007;**246**:665–71; discussion 671–4.
36. **Ukleja A**. Dumping syndrome: pathophysiology and treatment. *Nutr Clin Pract* 2005;**20**:517–25.
37. **Fein M**, Fuchs KH, Thalheimer A, Heimbucher J, Thiede A. Long-term benefits of Roux-en-Y pouch reconstruction after total gastrectomy: a randomized trial. *Ann Surg* 2008;**247**:759–65.
38. **Francis WP**, Rodrigues DM, Perez NE, Lonardo F, Weaver D, Webber JD. Prophylactic laparoscopic-assisted total gastrectomy for hereditary diffuse gastric cancer. *JSL S* 2007;**11**:142–7.
39. **Zhang X**, Tanigawa N, Nomura E, Lee SW. Curability of laparoscopic gastrectomy for gastric cancer: an analysis of 10 years' experience. *Gastric Cancer* 2008;**11**:175–80.
40. **Fitzgerald RC**, Caldas C. E-cadherin mutations and hereditary gastric cancer: prevention by resection? *Dig Dis* 2002;**20**:23–31.
41. **Miholic J**, Meyer HJ, Muller MJ, Weimann A, Pichlmayr R. Nutritional consequences of total gastrectomy: the relationship between mode of reconstruction, postprandial symptoms, and body composition. *Surgery* 1990;**108**:488–94.
42. **van Kouwen MC DJ**, Oyen WJ, de Bruin JH, Ligtenberg MJ, Bonenkamp JJ, van Krieken JH, Nagengast FM. [18F]Fluoro-2-deoxy-D-glucose positron emission tomography detects gastric carcinoma in an early stage in an asymptomatic E-cadherin mutation carrier. *Clin Cancer Res* 2004;**10**:6456–9.
43. **Oelschlagel BK**, Yigit T, Kaufman JA, Pellegrini CA. Hereditary diffuse gastric cancer. *MedGenMed* 2005;**7**:16.
44. **Newman EA**, Mulholland MW. Prophylactic gastrectomy for hereditary diffuse gastric cancer syndrome. *J Am Coll Surg* 2006;**202**:612–17.
45. **Chung DC**, Yoon SS, Lauwers GY, Patel D. Case records of the Massachusetts General Hospital. Case 22–2007. A woman with a family history of gastric and breast cancer. *N Engl J Med* 2007;**357**:283–91.
46. **Lynch HT**, Kaurah P, Wirtzfeld D, Rubinstein WS, Weissman S, Lynch JF, Grady W, Wiyrick S, Senz J, Huntsman DG. Hereditary diffuse gastric cancer: diagnosis, genetic counseling, and prophylactic total gastrectomy. *Cancer* 2008;**112**:2655–63.
47. **Caron O**, Schielke A, Svrcek M, Fléjou JF, Garzon J, Olschwang S, Sézeur A. Usefulness of prophylactic gastrectomy in a novel large hereditary diffuse gastric cancer (HDGC) family. *Am J Gastroenterol* 2008;**103**:2160–1.
48. **Gaya DR**, Stuart RC, McKee RF, Going JJ, Davidson R, Stanley AJ. E-cadherin mutation-associated diffuse gastric adenocarcinoma: penetrance and non-penetrance. *Eur J Gastroenterol Hepatol* 2005;**17**:1425–8.
49. **Gaya DR**, Stuart RC, Going JJ, Stanley AJ. Hereditary diffuse gastric cancer associated with E-cadherin mutation: penetrance after all. *Eur J Gastroenterol Hepatol* 2008;**20**:1249–51.
50. **Carneiro F**, Oliveira C, Suriano G, Seruca R. Molecular pathology of familial gastric cancer, with an emphasis on hereditary diffuse gastric cancer. *J Clin Pathol* 2008;**61**:25–30.
51. **Rubio CA**. Five types of pyloric cells in the antral mucosa of the stomach. *Pathol Res Pract* 1992;**188**:157–61.
52. **Zamboni G**, Franzin G, Scarpa A, Bonetti F, Pea M, Mariuzzi GM, Menestrina F. Carcinoma-like signet-ring cells in gastric mucosa-associated lymphoid tissue (MALT) lymphoma. *Am J Surg Pathol* 1996;**20**:588–98.
53. **Thompson IW**, Day DW, Wright NA. Subnuclear vacuolated mucous cells: a novel abnormality of simple mucin-secreting cells of non-specialized gastric mucosa and Brunner's glands. *Histopathology* 1987;**11**:1067–81.
54. **Lauren P**. The two histological main types of gastric carcinoma: diffuse and so-called intestinal-type carcinoma. an attempt at a histo-clinical classification. *Acta Pathol Microbiol Scand* 1965;**64**:31–49.
55. **Carneiro F**, Seixas M, Sobrinho-Simoes M. New elements for an updated classification of the carcinomas of the stomach. *Pathol Res Pract* 1995;**191**:571–84.
56. **Knudson AG Jr**. Mutation and cancer: statistical study of retinoblastoma. *Proc Natl Acad Sci U S A* 1971;**68**:820–3.
57. **Vlemincx K**, Vakaet L Jr, Mareel M, Fiers W, van Roy F. Genetic manipulation of E-cadherin expression by epithelial tumor cells reveals an invasion suppressor role. *Cell* 1991;**66**:107–19.
58. **Brooks-Wilson AR**, Kaurah P, Suriano G, Leach S, Senz J, Grehan N, Butterfield YS, Jeyes J, Schinas J, Bacani J, Kelsey M, Ferreira P, MacGillivray B, MacLeod P, Micek M, Ford J, Foulkes W, Australie K, Greenberg C, LaPointe M, Gilpin C, Nikkel S, Gilchrist D, Hughes R, Jackson CE, Monaghan KG, Oliveira MJ, Seruca R, Gallinger S, Caldas C, Huntsman D. Germline E-cadherin mutations in hereditary diffuse gastric cancer: assessment of 42 new families and review of genetic screening criteria. *J Med Genet* 2004;**41**:508–17.
59. **Corso G**, Roviello F, Paredes J, Pedrazzani C, Novais M, Correia J, Marrelli D, Cirnes L, Seruca R, Oliveira C, Suriano G. Characterization of the P373L E-cadherin germline missense mutation and implication for clinical management. *Eur J Surg Oncol* 2007;**33**:1061–7.
60. **Humar B**, Blair V, Charlton A, More H, Martin I, Guilford P. E-cadherin deficiency initiates gastric signet-ring cell carcinoma in mice and man. *Cancer Res* 2009;**69**:2050–6.
61. **Humar B**, Fukuzawa R, Blair V, Dunbier A, More H, Charlton A, Yang HK, Kim WH, Reeve AE, Martin I, Guilford P. Destabilized adhesion in the gastric proliferative zone and c-Src kinase activation mark the development of early diffuse gastric cancer. *Cancer Res* 2007;**67**:2480–9.